

Balloon REmodeling Antrostomy THERapy Study (BREATHE I) Case Study 1

MEDICAL HISTORY

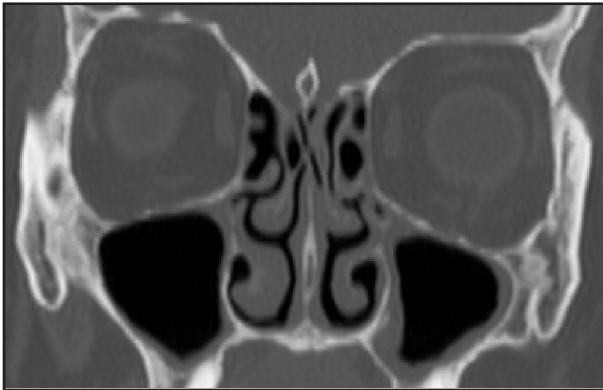
- 62-year old female
- Non-smoker with seasonal allergies and asthma
- Purulent drainage, post-nasal discharge, anosmia, GERD
- 30-year history of isolated maxillary rhinosinusitis
- 2 episodes within past 12 months; both treated with antibiotics and one with steroids

PROCEDURAL SUMMARY

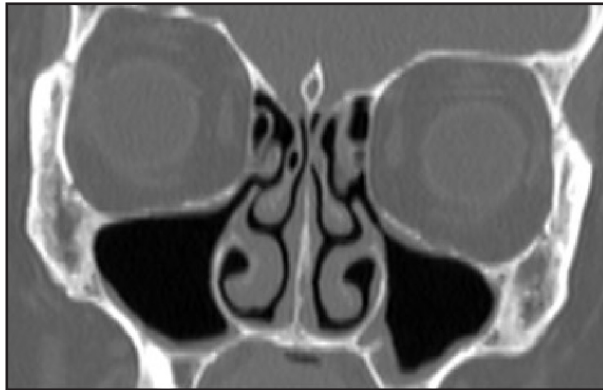
- Bilateral treatment in February 2008
- Local anesthesia with IV sedation

OUTCOMES

Pre-Procedure (Baseline) CT Scan



Follow-Up CT Scan at 1 Month



RESULTS

- Radiographic confirmation of patent ostia at 1-Month follow-up
- Symptomatic improvement sustained through 6-Month follow-up

Note: Subject enrolled and treated by Dr. Bradford Winegar at Austin Ear, Nose & Throat Clinic, Austin TX.

