

Early BREATHE I Clinical Results from a Novel System to Treat the Ethmoidal Infundibulum

Theodore Truitt MD¹, James Atkins MD², Douglas Liepert MD¹, Bradford Winegar MD³, Thomas Tami MD⁴, James Stankiewicz MD⁵

1-St. Cloud Ear, Nose & Throat – Head and Neck Clinic, St. Cloud, MN; 2-Texas Sinus Center, San Antonio, TX; 3-Austin Ear, Nose, and Throat Clinic, Austin, TX; 4-Cincinnati Sinus Institute, Cincinnati, OH; 5-Loyola University Medical Center, Chicago, IL

Introduction

One of the options for medically refractory chronic rhinosinusitis (CRS) is functional endoscopic sinus surgery (FESS). This involves removing tissue from the natural sinus outflow pathways often under general anesthesia^[1].

FESS evolved from more invasive procedures and has greatly improved the efficacy and recovery from sinus surgery. A new, effective technique for the treatment of obstructed sinus ostia uses balloon catheter technology to dilate and remodel sinus ostia with the benefit of preserving mucosa and minimizing trauma^[2]. However, intranasal anatomical variants, angle of the infundibulum, and nasal inflammation often present technical challenges to transnasal balloon dilation in the conscious patient. Therefore, a majority of these procedures have been performed under general anesthesia.

This study evaluates the clinical feasibility, safety, and early efficacy of using a trans-antral approach to balloon catheter dilation of the infundibulum and maxillary sinus ostium in the conscious patient.

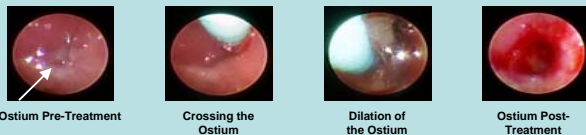
Methods

BREATHE I (Balloon REmodeling Antrostomy THERapy Study) is a prospective, multi-center study designed to evaluate the safety and efficacy of a system (RS-Series, Entellus Medical™) to treat patients with CRS of the maxillary or maxillary and anterior ethmoid sinuses.

Baseline evaluation includes medical history, physical examination with nasal endoscopy, CT imaging after maximum medical therapy, and completion of several quality of life questionnaires. Subjects are included if they have symptoms consistent with CRS and CT evidence of either a maxillary sinus air-fluid level or maxillary outflow obstruction with mucosal thickening ≥ 2 mm.

Prior to the index procedure, local anesthesia with or without conscious sedation is administered as necessary for pain management. Access to the maxillary antrum is obtained with a trocar, access sheath, and cannula. As shown in Figure 1, a flexible 0.5-mm endoscope is used to visualize the maxillary ostium and dilation is performed using either a 5-mm or 7-mm balloon^[3].

Figure 1: Trans-antral Endoscopic Visualization and Treatment of a Maxillary Sinus Ostium



Sino-Nasal Outcome Test (SNOT-20)^[4] scores are obtained at 1 week, 4 weeks, and 3 months postoperatively. A 3-month postoperative CT is taken to evaluate the patency of the infundibulum and status of the mucosal disease.

The study is being conducted under GCP (Good Clinical Practice) and all applicable CFR (Code of Federal Regulations) rules and requirements. Data analysis is conducted using commercially available software.

Results

Eighteen (18) subjects were enrolled between September 2007 and January 2008. Thirty-three (33) of thirty-four (34) ostia were successfully dilated for a treatment success rate of 97.1%. Baseline characteristics are shown in Table 1.

All subjects were treated under local anesthesia with or without light intravenous sedation as shown in Table 2 and discharged within 2 hours post-treatment.

There were 0 device malfunctions and none of the subjects were converted to FESS during or after the index procedure. The Wong-Baker (WB) pain rating scale (0 = No Hurt; 10 = Hurts Worst) was used to assess subject discomfort at the treatment site during the procedure and at discharge. The mean WB pain scores during the procedure and at discharge were 2.4 ± 2.6 and 1.8 ± 1.7 (2 = Hurts Little Bit) respectively.

Results (continued)

Table 1: Baseline Characteristics

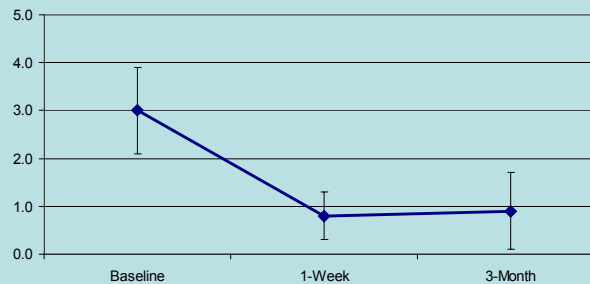
Characteristic	Total Number of Subject Treated [N = 18]		
	n	Mean +/- SD	Range
Age, years	18	47.1 +/- 13.9	24.2 – 77.9
	n	% (n/N)	
Gender			
Male	3	16.7% (3/18)	-
Female	15	83.3% (15/18)	-
Area of rhinosinusitis			
Maxillary and Anterior Ethmoid	6	33.3% (6/18)	-
Maxillary only	12	66.7% (12/18)	-
	n	Mean +/- SD	Range
Duration of rhinosinusitis, month	18	159.2 +/- 136.3	9.0 – 480.0
Number of times within the past 12 months the episodes were treated with antibiotics	-	4.6 +/- 2.1	2.0 – 8.0
Number of days of antibiotics for current episode	-	29.8 +/- 14.1	5.0 – 53.0

Table 2: Intra-operative Anesthesia Regimen

Anesthesia Used	n	% (n/N)
Local only	4	22.2% (4/18)
Local and IV sedation	14	77.8% (14/18)
General	0	0.0% (0/18)

Safety and efficacy have been evaluated through the review of adverse event (AE) data, assessment of patency at 3 months, and comparison of SNOT-20 scores through 3-month follow up. Patency as confirmed by radiographic imaging is 96.4%. Figure 2 shows the symptomatic improvement through 3 months as assessed by comparing the pre-procedure and post-procedure SNOT-20 scores. There have been 0 unanticipated adverse device effects (UADEs) and 0 serious device-related adverse events. There were two (2) mild device-related AEs for tooth numbness at 3-month follow-up. Both subjects reported minimal awareness of the event and each was easily tolerated.

Figure 2: Overall SNOT-20 Scores at 3-Month Follow-Up [N=18]



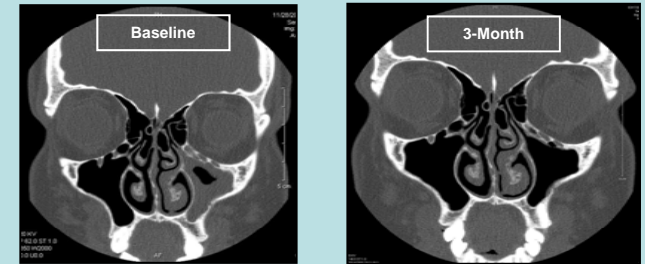
References

- Kennedy DW. Functional endoscopic sinus surgery. Technique. Arch Otolaryngol 1985;111:643-9.
- Bolger WE, Brown CL, Church CA, et al. Safety and efficacy of balloon catheter dilation of paranasal sinus ostia dilation. Otolaryngol Head Neck Surg 137:10-20, 2007.
- Truitt TO, Cutler J, Keith P, Ressemann T. Feasibility of endoscopic trans-antral maxillary outflow tract dilation. Poster, Meeting of the American Rhinologic Society, Orlando, FL, May 2008.
- Piccalillo, JF, Merritt, MG, Richards, M (2002) "Psychometric and Clinimetric Validity of the 20-Item Sino-Nasal Outcome Test (SNOT-20)" Otolaryngol Head Neck Surg 2002;126: 41-75.
- Harnesberger HR, Babbel RW, Davis WL. The major obstructive inflammatory patterns of the sinonasal region seen on screening sinus computed tomography. Seminars in Ultrasound, CT and MR, Vol 12, No. 6 (December), 1991: pp 541-560.
- Albu S, Tomescu E. Small and large middle meatus anrostomies in the treatment of chronic maxillary sinusitis. Otolaryngol Head Neck Surg 131(4):542-547, 2004.

Case Study

A 24-year old female presented with symptoms at baseline consistent with chronic maxillary sinus disease including sinus headaches, purulent drainage, post-nasal discharge, nasal congestion, maxillary sinus pressure, and anosmia. The subject underwent unilateral balloon dilation on December 13, 2007.

The baseline CT showed significant disease in the left maxillary sinus and obstruction of the infundibulum. The pre-operative SNOT-20 score was 3.8. At the 3-month follow-up, radiological evaluation confirmed complete resolution of the mucosal thickening in the maxillary sinus and infundibulum. Symptomatic improvement was confirmed by a SNOT-20 score of 0.2.



Discussion and Conclusions

Endoscopic sinus surgery is directed at improving sinus outflow and is the current standard of care intervention to treat CRS. A review of radiographic imaging has shown 26% of subjects with sinusitis and findings on CT have patterns of obstruction to the infundibulum (maxillary sinusitis only) and 25% have an obstructive pattern of the ostiomeatal unit (maxillary sinusitis with anterior ethmoid and/or frontal sinusitis). Both patterns involve obstruction of the maxillary sinus with or without involvement of the anterior ethmoid sinuses^[5]. Although less invasive than its predecessors for these patterns, FESS frequently employs the use of general anesthesia and may result in scarring or adhesions within the ostiomeatal unit.

This study shows that performing balloon dilation of the infundibulum in conscious subjects through the canine fossa is well-tolerated with minimal discomfort and can be completed with a high degree of procedural success. Because mucosal tissue and the uncinate process are preserved during catheter dilation, this novel approach may be a less-invasive alternative to FESS with traditional instruments and trans-nasal balloon dilation. Additionally, these early results show that treatment of the maxillary ostia and infundibulum via trans-antral balloon dilation is safe and effective in treating chronic maxillary sinus disease alone or with involvement of the anterior ethmoid sinuses.

Understanding the underlying mechanisms of action and physiologic changes that result in symptomatic and radiographic improvement post balloon dilation remains an important area of research. The literature has suggested that outcomes from small maxillary anrostomies may be as effective as those from large anrostomies^[6]. For balloon anrostomy, it is theorized that tissue preservation in conjunction with anatomical remodeling in both the lateral to medial plane and anterior to posterior plane of the infundibular region yields enough improvement to the natural drainage pathway to effectively treat CRS. However, measurement of the dimensional changes of the infundibulum remains challenging, and opportunity for future research includes quantitative assessment of the impact of dilation on the volume of the infundibulum.

The 3-month data from the first 18-subject cohort of the larger BRFATHE I study show access to, and balloon dilation of, the maxillary sinus outflow tract is safe and can be achieved with a high level of success resulting in statistically-significant, symptomatic improvement in SNOT-20 scores. Future data will be presented when available.